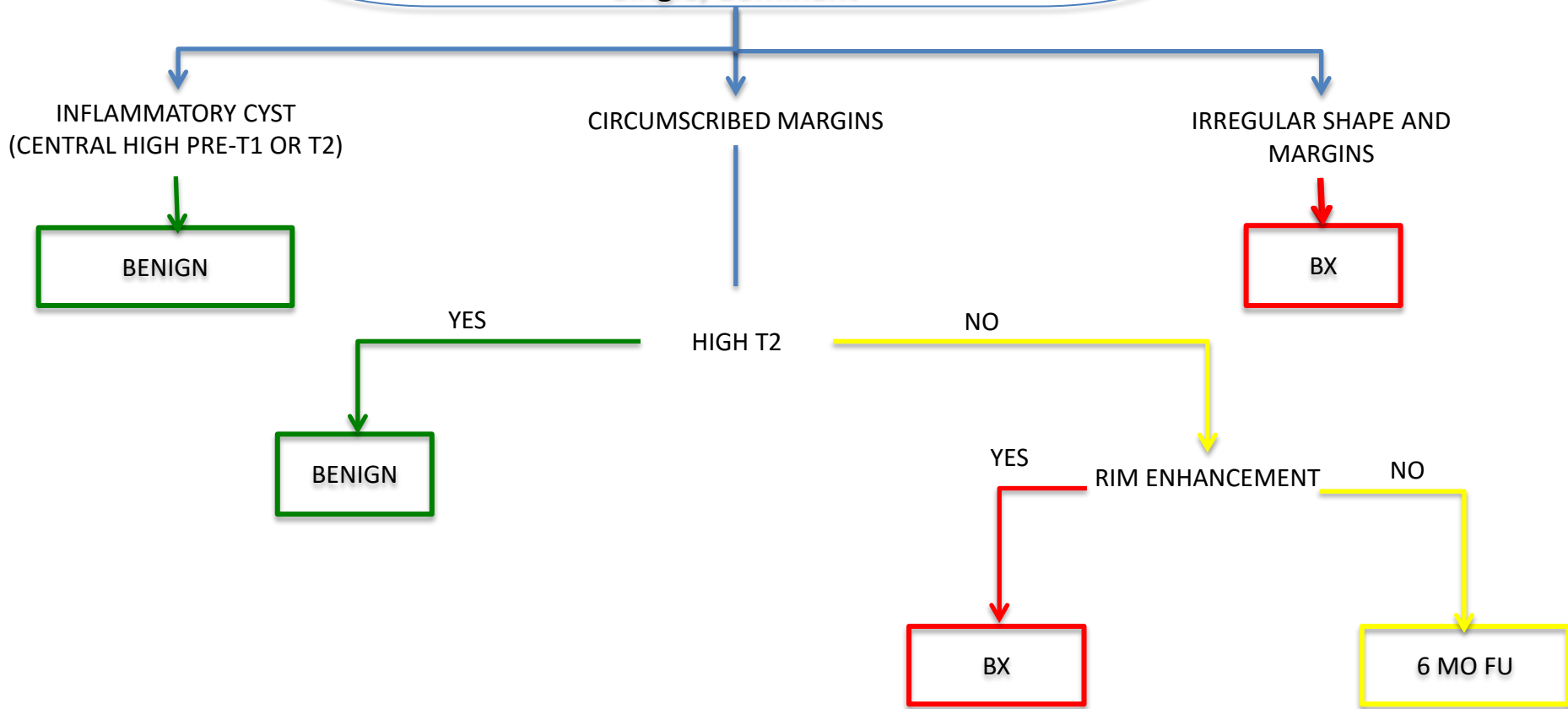
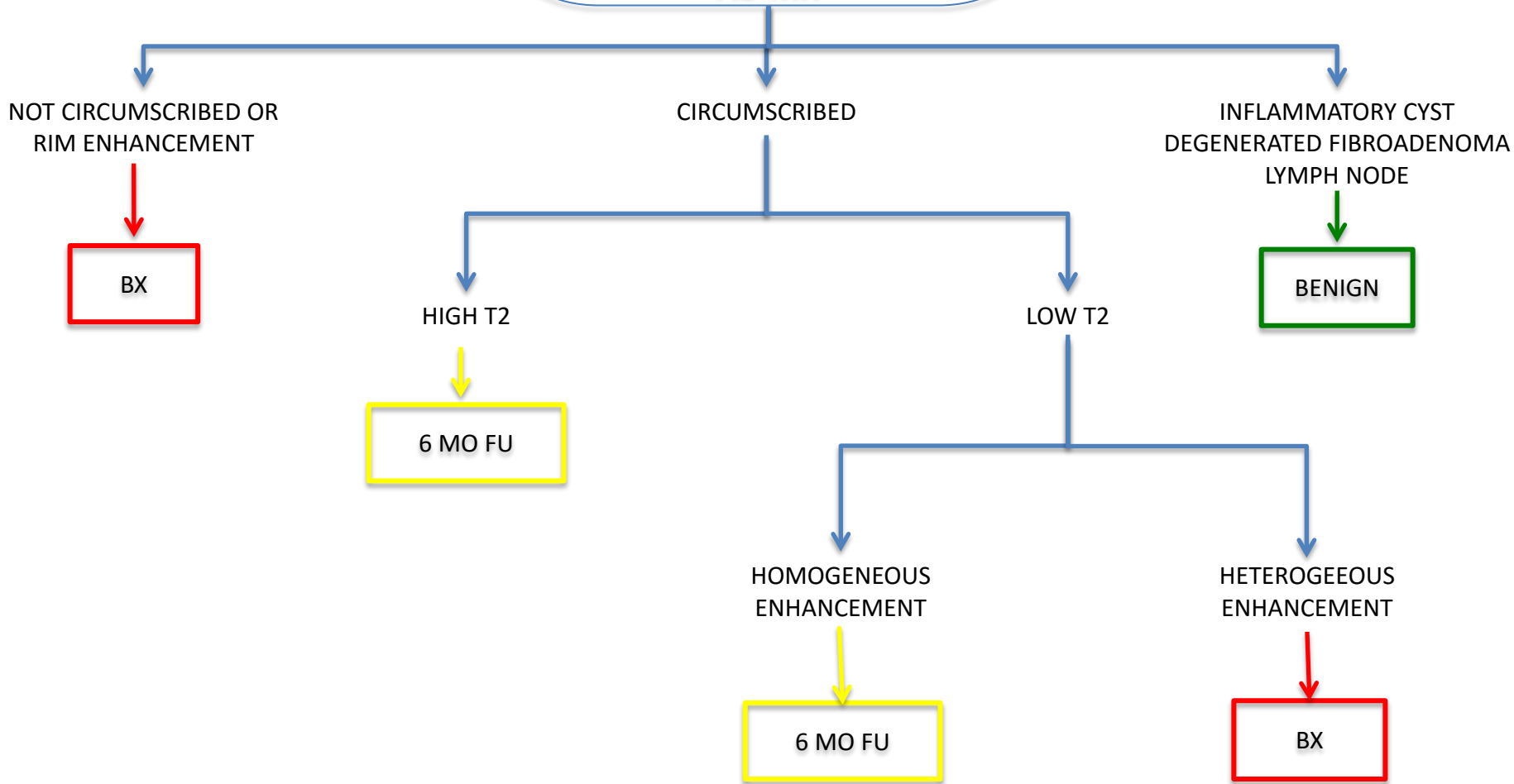


**Unique 3- <5 mm Focus on Baseline AB-MR:
Single, dominant**

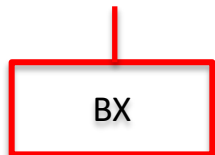


**Unique Mass on Baseline
AB-MR**



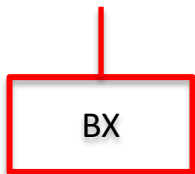
Unique Non-Mass Enhancement on Baseline AB-MR

DISTRIBUTION:
LINEAR, SEGMENTAL



DISTRIBUTION:
FOCAL, REGIONAL, MULTIPLE REGIONS, DIFFUSE

INTERNAL ENHANCEMENT:
CLUMPED
HETEROGENEOUS
CLUSTERED RING



INTERNAL ENHANCEMENT:
HOMOGENEOUS

ASSOCIATED FIBROCYSTIC CHANGE
ON T2

YES

NO

